

TIPS FROM OUR READERS

An alternative technique for transferring denture-related soft tissue irritation to the denture



Ju-Hyoung Lee, DDS^a and Cheong-Hee Lee, DDS, PhD^b

The most critical time in the success or failure of a denture is the adjustment period, and the most common complaint is pain caused by soft tissue irritation.¹⁻³ The clinician is responsible for the care of the patient throughout this period; however, detecting and transferring the irritated area to the denture is difficult because the irritated soft tissue is frequently located in the posterior area.^{1,4} As Loney and Knechtel⁵ emphasized, pressure-indicating paste is useful for improving the diagnosis and correction of denture-related problems. An indelible pencil is also used for transferring the irritated area to the denture.⁶ However, approaching and marking the posterior irritated area with a straight pencil is difficult, especially in the maxillary tuberosity, mylohyoid ridge, or retromylohyoid area, while restraining tongue movement and maintaining dry conditions around the irritated soft tissue.

This article describes an alternative technique for marking the irritated area with calcium hydroxide paste. A disposable, thin, and angled syringe tip of the root canal medicament can be used to approach and mark the irritated area easily and to decrease the risk of cross infection. Even though calcium hydroxide paste is more expensive than pressure-indicating paste, it allows the accurate transference of a yellow mark from the irritated area to the denture base and prevents unnecessary grinding of the denture base. However, the topical application of polyvinyl siloxane material or pressure-indicating paste on the corresponding area of the denture base is also recommended for evaluating the intensity of the pressure spot because, like the indelible

pencil, calcium hydroxide paste provides only the location.

PROCEDURE

1. After the occlusion has been evaluated and corrected, find the irritated soft tissue.¹
2. Dry the intaglio surface of the denture.
3. Dry the irritated area with air. Apply a calcium hydroxide endodontic medicament (Vitapex; Neo Dental Intl) around the soft tissue irritation (Fig. 1).

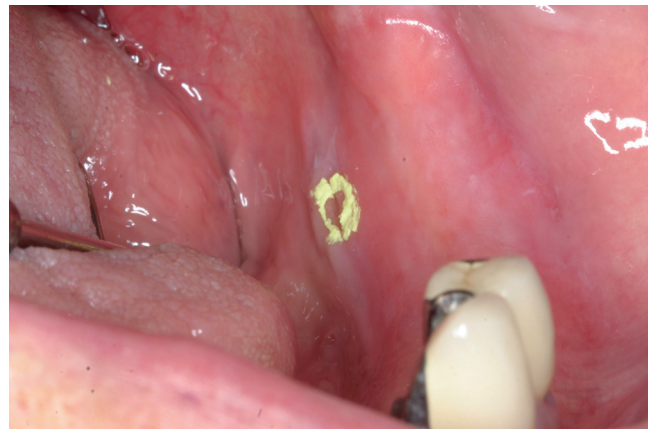

Figure 1. Marked soft tissue irritation in retromylohyoid area with calcium hydroxide paste.

^aAssistant Professor, Department of Dentistry, Catholic University of Daegu School of Medicine; Graduate Student, Department of Prosthodontics, School of Dentistry, Kyungpook National University, Daegu, South Korea.

^bProfessor, Department of Prosthodontics, School of Dentistry, Kyungpook National University, Daegu, South Korea.

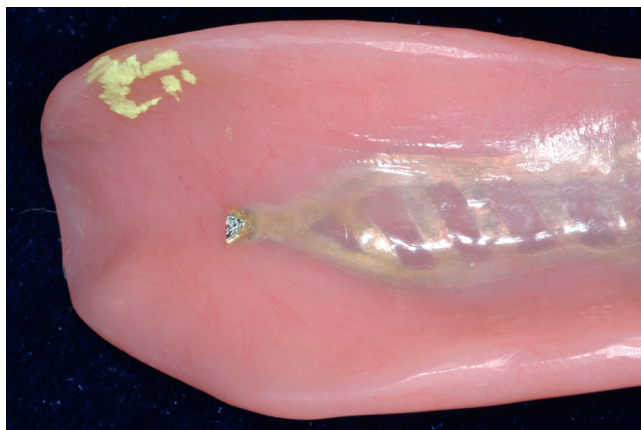


Figure 2. Corresponding area on intaglio surface of denture base.

4. Insert the denture along the path of placement and press on the occlusal surfaces of the artificial teeth in a vertical direction.^{5,7,8}
5. Remove the denture along the path of placement and interpret the yellow area on the intaglio surface of the denture (Fig. 2).
6. Carefully relieve this area with a laboratory bur (Volcano; Edenta).

REFERENCES

1. Zarb G, Hobkirk JA, Eckert SE, Jacob RF, Fenton AH, Finer Y, et al. Prosthodontic treatment for edentulous patients: complete dentures and implant-supported prostheses. 13th ed. St. Louis: Mosby; 2013. p. 275-80.
2. Smith JP, Hughes D. A survey of referred patients experiencing problems with complete dentures. J Prosthet Dent 1988;60:583-6.
3. Brunello DL, Mandikos MN. Construction faults, age, gender, and relative medical health: factors associated with complaints in complete denture patients. J Prosthet Dent 1998;79:545-54.
4. Kivovics P, Jahn M, Borbély J, Márton K. Frequency and location of traumatic ulcerations following placement of complete dentures. Int J Prosthodont 2007;20:397-401.
5. Loney RW, Knechtel ME. Diagnosing denture problems using pressure-indicating media. J Prosthet Dent 2009;101:137-41.
6. Phoenix RD, Cagna DR, DeFreest CF. Stewart's clinical removable partial prosthodontics. 4th ed. Chicago: Quintessence; 2008. p. 447-50.
7. Carr AB, Brown DT. McCracken's removable partial prosthodontics. 12th ed. St. Louis: Elsevier; 2011. p. 289-91.
8. Boucher LJ. Insertion adjustment of denture base surface contacting the mylohyoid ridge. J Prosthet Dent 1992;67:900-1.

Corresponding author:

Dr Ju-Hyoung Lee
 Catholic University of Daegu School of Medicine
 3056-6 Daemyung-4-Dong
 Namgu, Daegu
 SOUTH KOREA
 Email: jus2u@cu.ac.kr

Copyright © 2015 by the Editorial Council for *The Journal of Prosthetic Dentistry*.

Print subscribers have access to *The Journal of Prosthetic Dentistry* online!

Full-text access to *The Journal of Prosthetic Dentistry Online* is available for all print subscribers. To activate your individual online subscription, please visit *The Journal of Prosthetic Dentistry Online*. Point your browser to <http://www.journals.elsevierhealth.com/periodicals/ympr/home>, follow the prompts to **activate online access here**, and follow the instructions. To activate your account, you will need your subscriber account number, which you can find on your mailing label (*note*: the number of digits in your subscriber account number varies from 6 to 10). See the example below in which the subscriber account number has been circled.

Sample mailing label

*****AUTO**SCH 3-DIGIT 001

1 V97-3 J010 (12345678-9)

J. H. DOE
 531 MAIN ST
 CENTER CITY, NY 10001-001

This is your subscription account number →

Personal subscriptions to *The Journal of Prosthetic Dentistry Online* are for individual use only and may not be transferred. Use of *The Journal of Prosthetic Dentistry Online* is subject to agreement to the terms and conditions as indicated online.