

TIPS FROM OUR READERS

Accurate repositioning of an implant interim restoration into the definitive impression to obtain an exact reproduction of tissue contours in the soft tissue cast



Jimmy Londono, DDS,^a Alvaro Blasi, DDS,^b Jasmine Silas, DMD,^c and Amara Abreu, DDS, MSD^d

Detailed reproduction of the soft tissue surrounding the implant is essential to the passive fit of implant restorations, and even small discrepancies may result in complications during the fabrication and insertion of the definitive crown. A method is presented here for transferring precise tissue contours to the definitive cast by using the interim restoration as an impression coping, simultaneously helping to mold the peri-implant tissue.^{1,2} Soft tissue becomes modifiable after controlled and constant compression. The peri-implant mucosa can be sculpted³ by removing and modifying the interim restoration every 1 or 2 weeks for up to 2 months.⁴⁻⁷

Using interim restorations as impression copings provides specifics related to soft tissue, incisal edge position, and crown contours. Placing composite resin on the facial surface of the interim restoration allows its exact repositioning within the impression. It also stabilizes it to produce the most accurate replica in stone, preventing minor discrepancies because of movement during the laboratory procedures.

PROCEDURE

1. Insert the interim restoration in the patient's mouth, add bonding agent (Optibond FL; Kerr Corp), and place the composite resin (Premise Body; Kerr Corp) on the facial surface of the interim restoration to

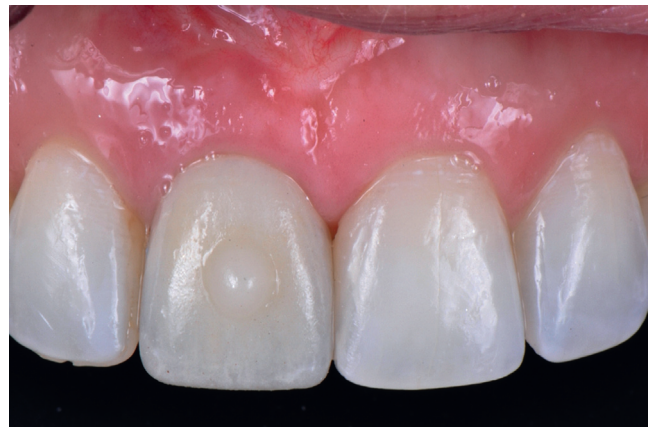

Figure 1. Frontal view of composite resin button on facial surface of implant interim crown.

- form a 2-mm-diameter button. Light polymerize. (Fig. 1)
2. Make an implant-level impression using polyvinyl siloxane impression material (Extrude Extra-High Consistency, Extrude-Low Consistency; Kerr Corp) (Fig. 2A).
3. Remove the interim restoration, and secure it with the implant analog (Nobel Active 4.3 mm diameter; Nobel Biocare). Insert this assembly into the definitive impression by using the negative of the

^aAssociate Professor, Department of Restorative Sciences, Dental College of Georgia, Augusta University, Augusta, Ga.

^bPrivate practice, Barcelona, Spain.

^cGraduate student, Graduate Prosthodontics, Department of Restorative Sciences, Dental College of Georgia at Augusta University, Augusta, Ga.

^dAssociate Professor and Section Director-Removable Prosthodontics, Department of Restorative Sciences, Dental College of Georgia, Augusta University, Augusta, Ga.

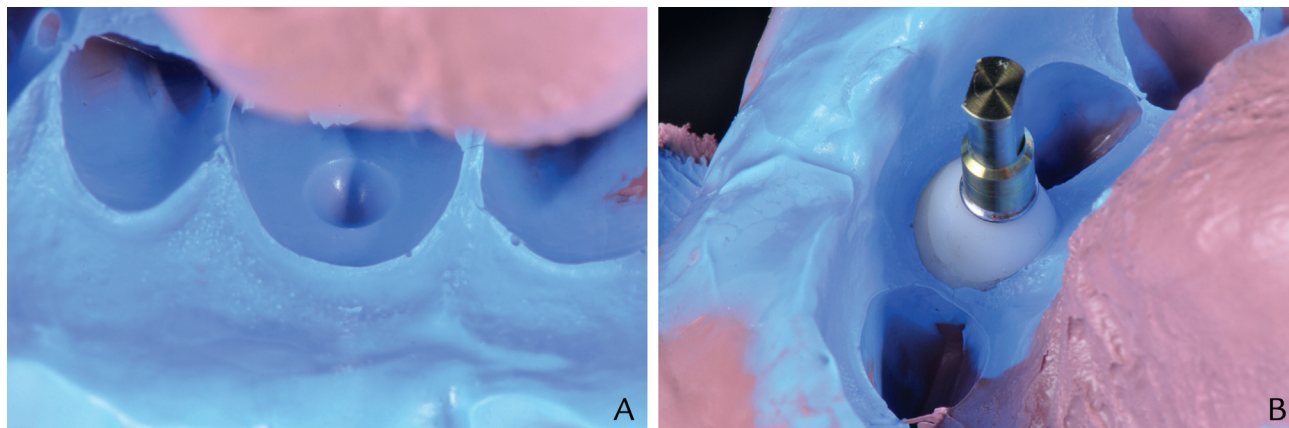


Figure 2. A, Polyvinyl siloxane implant level impression. B, Interim restoration/implant analog assembly inserted into implant level impression.

composite resin button as a reference for correct positioning. (Fig. 2B)

4. Pour soft tissue cast in Type 3 dental stone (Microstone; Whip Mix Corp).
5. Fabricate the definitive crown.

REFERENCES

1. Tsai BY. Use of provisional restorations as implant impression copings. *J Prosthet Dent* 2007;97:395-6.
2. Tsai BY. A method for obtaining peri-implant soft-tissue contours by using screw-retained provisional restorations as impression copings: a clinical report. *J Oral Implantol* 2011;37:605-9.
3. Parpaiola A, Sbricoli L, Guazzo R, Bressan E, Lops D. Managing the peri-implant mucosa: a clinically reliable method for optimizing soft tissue contours and emergence profile. *J Esthet Restor Dent* 2013;25:317-23.
4. Ntounis A, Petropoulou A. A technique for managing and accurate registration of peri-implant soft tissues. *J Prosthet Dent* 2010;104:277-9.
5. Spyropoulou PE, Razzoog M, Sierraalta M. Restoring implants in the esthetic zone after sculpting and capturing the peri-implant tissues in rest position: a clinical report. *J Prosthet Dent* 2009;102:345-7.
6. Paul SJ, Joranovic SA. Anterior implant supported reconstruction: a prosthetic challenge. *Pract Periodontics Aesthet Dent* 1999;11:585-90.
7. Kourtis S, Psarri C, Andritsakis P, Doukoudakis A. Provisional restorations for optimizing esthetics in anterior maxillary implants: a case report. *J Esthet Restor Dent* 2007;19:6-17.

Corresponding author:

Dr Amara Abreu
 Department of Restorative Sciences
 Dental College of Georgia at Augusta University
 1120 15th St, GC4228
 Augusta, GA 30912
 Email: aabreu@augusta.edu

Copyright © 2018 by the Editorial Council for *The Journal of Prosthetic Dentistry*.
<https://doi.org/10.1016/j.prosdent.2018.03.021>