

TIPS FROM OUR READERS

Using an existing surgical template as an aid for a virtual interocclusal record



Wei-Shao Lin, DDS,^a Hawra AlQallaf, BDM, MSD,^b and Dean Morton, BDS, MS^c

A satisfactory complete denture can be duplicated with acrylic resin to preserve the information on the patient's occlusal vertical dimension, occlusal relationship, and tooth arrangement during preoperative planning for dental implant treatment.¹ The duplicated denture can be used as a radiographic template, surgical template, and occlusally adapted custom tray.² A dual scan protocol with the existing complete denture and additively manufactured surgical template (in the shape of a duplicated denture) is commonly used in contemporary static computer-aided implant surgery (s-CAIS). Occlusion with the opposing arch is often needed to properly position these surgical templates before the s-CAIS.³ As these surgical templates are designed and manufactured

from the 3D volumetric data of the existing denture, preserving the interocclusal relationship, this technique allows the clinicians to use the surgical template as an aid to obtain a virtual interocclusal record during intraoral scanning. The acquired intraoral scan and virtual interocclusal record can be used for fabricating a computer-aided design and computer-aided manufacturing (CAD-CAM) implant prosthesis.

TECHNIQUE

1. Plan the s-CAIS according to the collected diagnostic data and design the surgical template incorporating the existing denture occlusion. Use the

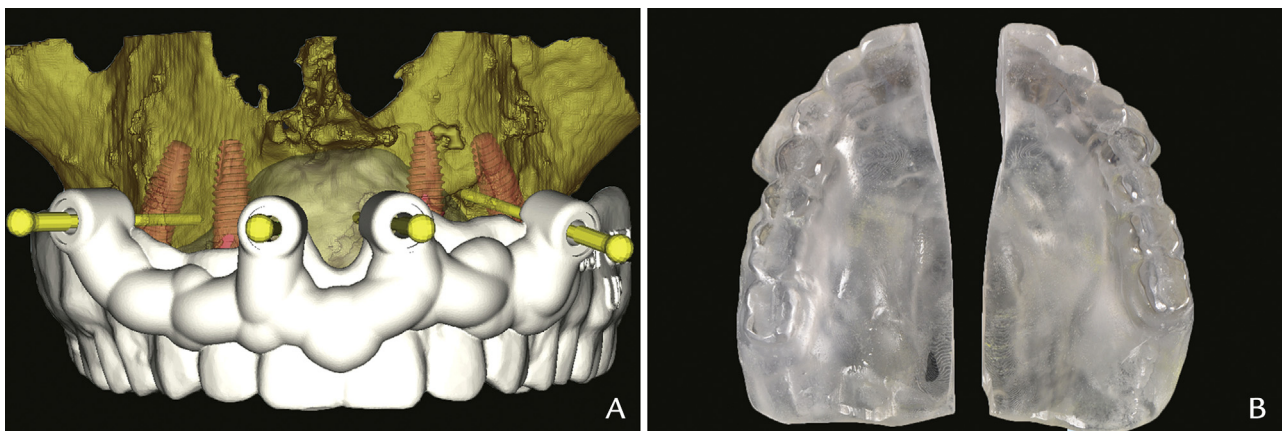


Figure 1. A, Computer-aided design and computer-aided manufacturing (CAD-CAM) surgical template design. B, Sectioned surgical template.

^aAssociate Professor and Program Director, Advanced Education Program in Prosthodontics, Department of Prosthodontics, Indiana University School of Dentistry, Indianapolis, Ind.

^bVisiting Clinical Assistant Professor, Department of Periodontology, Indiana University School of Dentistry, Indianapolis, Ind.

^cProfessor, Department of Prosthodontics, Indiana University School of Dentistry, Indianapolis, Ind.

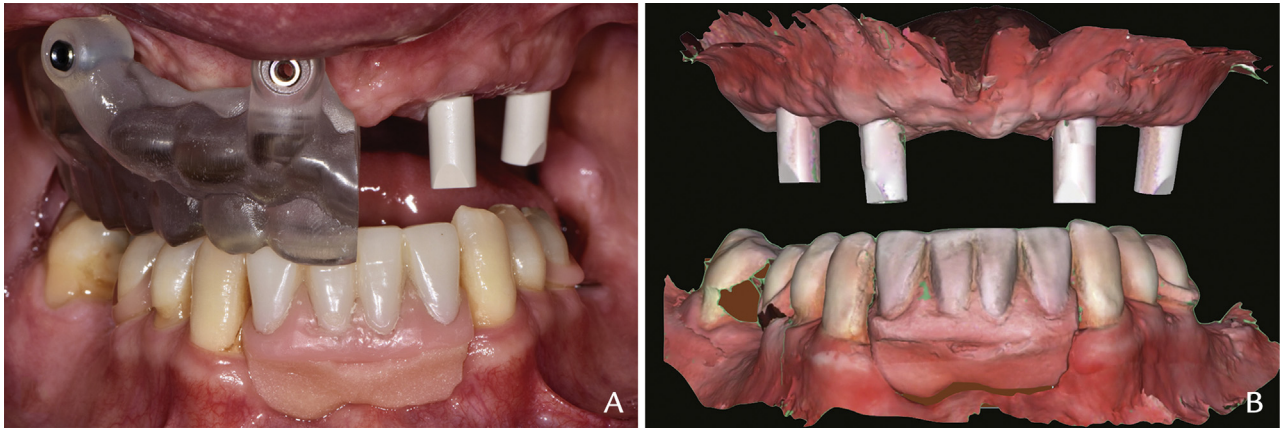


Figure 2. A, Interocclusal relationship maintained by sectioned surgical template. B, Complete intraoral scans at interocclusal relationship.

opposing occlusion to position the surgical template and perform s-CAIS accordingly (Fig. 1A).

- Evaluate the dental implants after the healing period. Use a laboratory diamond disk (NTI Serrated Diamond Disc; Kerr Corp) to section the surgical template at the midline (Fig. 1B).
- Secure the scannable impression copings (Mono scanbody for screw-retained abutment; Institut Straumann AG) to the implants and complete the maxillary and mandibular intraoral scans by using an intraoral scanner (Virtuo Vivo; Institut Straumann AG).
- Remove the scannable impression copings in the maxillary right region and place the corresponding sectioned surgical template intraorally. Examine the interocclusal relationships provided by the sectioned surgical template and adjust the occlusion if necessary (Fig. 2A).
- Scan the virtual interocclusal record from the left buccal aspect.
- Reposition the scannable impression copings in the maxillary right region and remove the impression copings on the contralateral side. Place the corresponding sectioned surgical template intraorally and complete the remaining virtual interocclusal record (Fig. 2B).
- Transfer the acquired maxillary and mandibular intraoral scans and virtual interocclusal record to the dental laboratory for the fabrication of interim or definitive implant prostheses.

DISCUSSION

This technique may offer a convenient way of using an existing surgical template as an aid to obtain a virtual interocclusal record during intraoral scanning. The original complete denture and surgical template should have a satisfactory interocclusal relationship. This technique is more suitable for the maxillary edentulous patient, as the hard palate remains unchanged before and after s-CAIS and provides a consistent seating area for repositioning the surgical template. In the event of significant post-operative soft-tissue changes, denture reline material can be used to improve the intaglio adaptation before sectioning the surgical template.

REFERENCES

- Tarlow JL. Fabrication of an implant surgical stent for the edentulous mandible. *J Prosthet Dent* 1992;67:217-8.
- Wulfman C, Hadida A, Rignon-Bret C. Radiographic and surgical guide fabrication for implant-retained mandibular overdenture. *J Prosthet Dent* 2010;103:53-7.
- Orentlicher G, Horowitz A, Kobren L. Computer-guided dental implant treatment of complete arch restoration of edentulous and terminal dentition patients. *Oral Maxillofac Surg Clin North Am* 2019;31:399-426.

Corresponding author:

Dr Wei-Shao Lin
Indiana University School of Dentistry
Department of Prosthodontics
1121 W. Michigan Street, Office: DS-S406
Indianapolis, IN 46202-5186
Email: weislin@iu.edu

Copyright © 2019 by the Editorial Council for *The Journal of Prosthetic Dentistry*.
<https://doi.org/10.1016/j.prosdent.2019.11.009>